

## Case Report

### Vascular Malformation in the Mandible and Maxilla: An Interesting Case Series

Cleverson Patussi, Laurindo Moacir Sassi, Regiane Benez Bixofis, Fernando Luiz Zanferrari, Roberta Targa Stramandinoli-Zanicotti, Juliana Lucena Schussel

#### Abstract

Vascular malformations are anomalies that occur in vascular morphogenesis that are present at birth and can become evident due an event like trauma, surgery or infection. This pathology was previously classified as hemangioma and the treatment continues controversial in literature. **Series of Cases:** We report three cases of intra osseous vascular malformations in the face, one in maxilla and two in the mandible. Patients had a mean age of 15 years old with complain of increase of volume in middle and lower third of the face without associated symptoms. They presented radiographic alterations such as lobulations or different osseous density. All patients underwent biopsy with abundant hemorrhage without other particularities as well none unusual tissue fragment for histological analyses. **Conclusion:** Vascular malformations require careful diagnosis and multidisciplinary approach in order to avoid complications or misconduct. The knowledge of the nature of the pathology helps monitoring the patients and prevents accidents.

**Keywords:** Arteriovenous Malformations; Hemangioma; Hemorrhage; Intraosseous; Vascular Anomalies; Vascular Malformation.

*Cleverson Patussi, Laurindo Moacir Sassi, Regiane Benez Bixofis, Fernando Luiz Zanferrari, Roberta Targa Stramandinoli-Zanicotti, Juliana Lucena Schussel. Vascular Malformation in the Mandible and Maxilla: An Interesting Case Series. International Journal of Oral & Maxillofacial Pathology; 2014;5(1):37-41. ©International Journal of Oral and Maxillofacial Pathology. Published by Publishing Division, Celesta Software Private Limited. All Rights Reserved.*

#### Introduction

Vascular malformations are errors in vascular morphogenesis that are present at birth and become evident due to an event like trauma, surgery or infection, that was previously classified as hemangiomas.<sup>1,2</sup> The first classifications adopted for vascular anomalies would only describe specific lesions. Successively, new classifications based on pathological and embryological findings and classifications based on biological behavior of the lesion were suggested. The lack of international diagnostic classification did not, until recently, help to determinate appropriate therapy, which complicates the creation of a treatment protocol and compromises the comparison between different treatment options.<sup>1,2</sup> Arteriovenous malformations or vascular malformations of jaw are extremely rare conditions that can result in disastrous complications, if handled carelessly. This kind of lesion has an overall 2:1 female/male occurrence, with peak incidence in the second decade of life, with extremes at 3 months and 74 years of age. Although more than 50% of vascular lesions occur in the head and neck region, only a small percentage of cases occur in the jaws, being twice more common in the mandible than in the maxilla.<sup>3</sup> This lesion usually presents clinically as a hard slow growing mass in the

face. The most usual symptoms include facial deformity, hemorrhage, headaches, proptosis, and diplopia. Sometimes vascular malformations may be asymptomatic and present as radiographic finding. The diagnosis usually is difficult unless there are a sign that suggest a vascular lesion. Rarely, they can have a radiopaque appearance.<sup>4,5</sup>

As the lesion is benign and presents a slow growth, the treatment is usually performed for aesthetic and cosmetic reasons, of which the most common procedure is excision with bone reconstruction, which leads to rare recurrence. Other treatment modalities include angiography with embolization, radiation, curettage, sclerosing agent, and cryotherapy.<sup>3-5</sup> More recently, the use of beta-blockers in the treatment of vascular malformations have shown good results with significant reduction of the vascular mass in a short period of time.<sup>2</sup> The aim of the study is to present a series of three cases of vascular malformations in face - two in the mandible and one in maxilla- of patients referred to the service of Oral and Maxillofacial Surgery of the Erasto Gaertner Hospital - Curitiba, Brazil.

#### Case Reports

All patients signed an Informed Consent Term authorizing this report.

### Case 1

Male patient, 15 years old, was referred to the service of Oral and Maxillofacial Surgery of the Erasto Gaertner Hospital with a lesion in the right side of mandible. An extra oral examination (Figure 1a) revealed a discrete volume increase on the right side of the mandible and the intra oral examination (Figure 1b) showed a complete upper and lower dentition, with satisfactory oral hygiene and the presence of a significant lingual volume increase on the right side of the mandible. A grade I mobility of the teeth 44, 45, 46 and 47 was observed as well the absence of the tooth 48. Arteriography (Figure 1c) demonstrating vascular defect of the lesion. Panoramic radiograph (Figure 1d) showed multilobulated osteolytic lesion on the right side of the mandible with intralesional trabecular bone. The lesion was approximately 5 cm in its largest diameter, from mesial of tooth 44 to distal of tooth 47. It could also be observed increased of volume between the upper and lower cortical of the mandible. At the time of the clinical and radiographic examination differential diagnosis included central giant cell lesion, odontogenic cysts, and benign tumors like ameloblastoma and keratocystic odontogenic tumor. A biopsy was performed and an important hemorrhage was a complication during the procedure. Although no conclusive histological analysis could have been made, the surgical findings evidenced the vascular nature of the lesion.

### Case 2

Male patient, 15 years old, referred to the service of Oral and Maxillofacial Surgery of the Erasto Gaertner Hospital complaining of swelling in the right side of the mandible. Extra oral examination (Figure 1e) showed mild swelling of the lower third of the face on the right side. Intra oral examination showed complete dentition and mucosa with normal color with presence of a swelling of the right mandible in the region of teeth 46 and 47 and an exophytic reddish lesion with approximately 1 cm in diameter in the same region. The lesion would bleed at minimum touch and the 47 tooth presented mobility and severe extrusion. Panoramic radiograph and computed tomography (Figure 1f) showed a well-circumscribed osteolytic lesion in the right side mandible, from the apex of teeth 46 and 47 to the region of the germ of tooth 48, with no reabsorption of the cortical bone. Differential diagnosis like ameloblastoma, odontogenic cysts, central giant cell granuloma could be listed as initial

diagnostic hypothesis based on the clinical and radiological findings. An incisional biopsy of the exophytic lesion was performed, and histopathological analysis suggested a peripheral giant cell granuloma. A surgical procedure for biopsy and extraction of tooth 47 under general anesthesia was planned. The procedure leads to abundant hemorrhage indicating the vascular character of the lesion. Histopathological analysis showed as a vascular malformation associated to peripheral giant cell granuloma.

### Case 3

Female patient, 15 years old, presented to the service of Oral and Maxillofacial Surgery of the Erasto Gaertner Hospital with swelling in the region of the jaw on the right side of the face. Intra oral examination (Figure 1g) it was observed complete dentition with good oral hygiene and volume increase in maxillary vestibule on the right side with normal consistency. The extra oral examination showed a slight volume increase. Panoramic radiograph showed (Figure 1h) diffuse injury without defined limits in the maxilla on the right side with about 7 cm in diameter without extrusion of teeth or other bone disorders observed. Benign tumors such as ameloblastoma, central giant cell granuloma, bone dysplasia and osseous exostosis were included as differential diagnosis. In trans-operative procedure for biopsy, important bleeding at the time of access of the injury was observed, and no material was collected since the only finding was vascular proliferation.

### Discussion

The diagnosis of vascular malformations is not always simple and easy to perform. This type of injury has no specific pathognomonic characteristics and behaviors that differentiate other bone injuries. These alterations goes into differential diagnosis of a number of bone lesions as odontogenic and inflammatory cysts, benign tumors such as central giant cell lesion, hemangiomas, ameloblastomas and even malignant lesions.<sup>6,7</sup> Hemangiomas show many dilated, thin-walled vascular spaces lined by benign endothelial cells separated by bone septum and fibrous stroma supporting the blood-filled vascular spaces.<sup>3,4</sup> Nevertheless, histopathological diagnosis can be tricky and may demand immunohistochemical analysis for closure. Among the markers of cell proliferation, it has been noted that there is

elevation of vascular endothelial growth factor and basic fibroblast growth factor.<sup>1</sup> Recent studies showed immunoexpression of glucose-transporter-1 in hemangioma

suggesting that this marker could be used for definitive diagnosis of hemangioma, differentiating from other vascular malformation.<sup>2</sup>

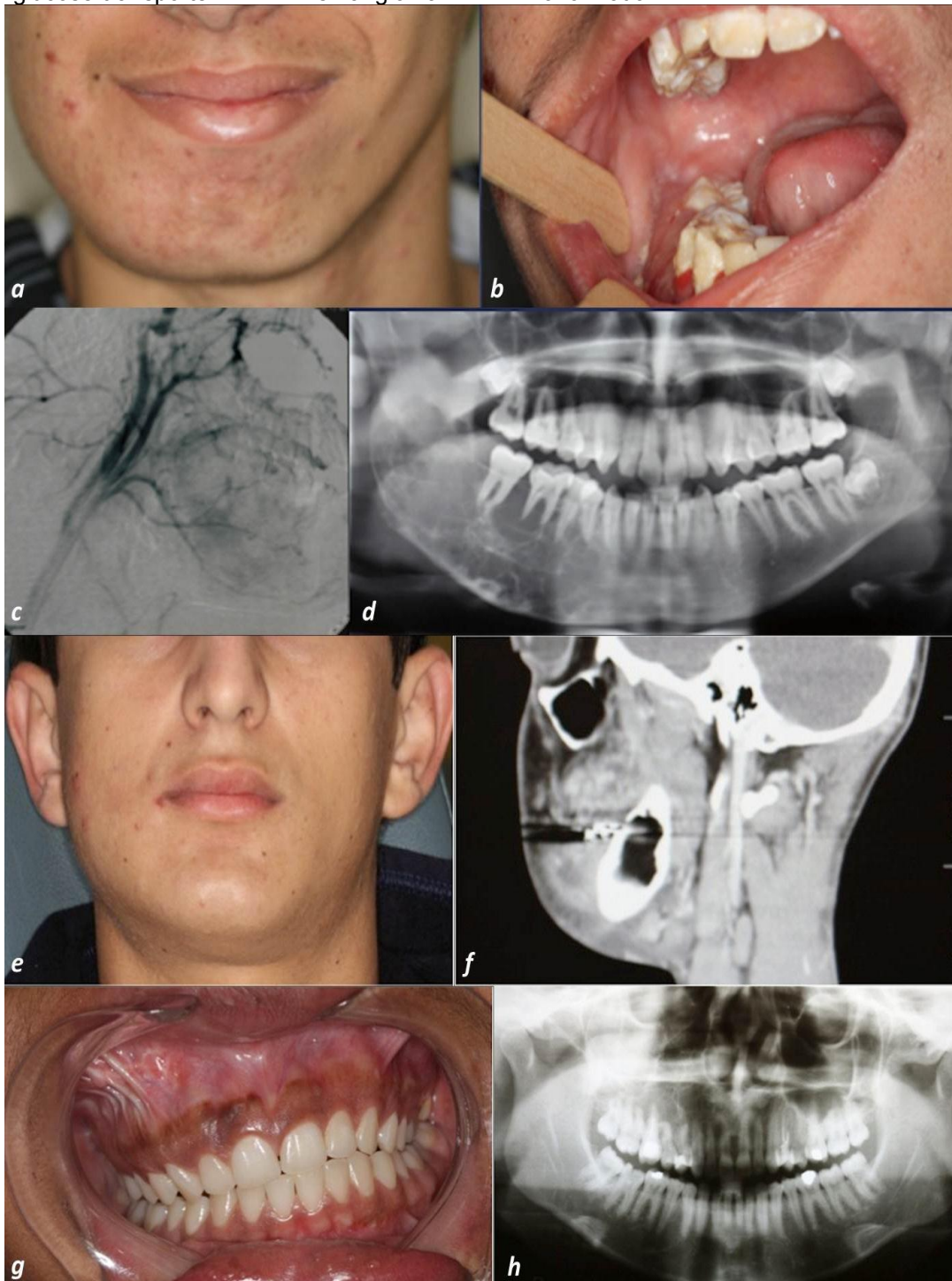


Figure 1: The case 1 showing extra (a) and intra (b) oral aspect of swelling in the right mandible with arteriography demonstrating vascular defect of the lesion (c) and panoramic radiograph showing lobulation in mandible (d). The case 2 showing extra oral examination with increase of volume in mandible on right side (e) and computerized tomography showing hypodensity in the area of the lesion (f). The case 3 showing intra oral swelling on left side of maxilla (g) and panoramic radiograph showing lobulated aspect in right maxilla (h).

The main complaint of patients with this kind of injury is the esthetic disturbance.

Depending on size and location, can cause facial asymmetry or interfere with the

function of the involved organs. When located on the floor of the mouth or mandible, these lesions cause functional problems associated with chewing, swallowing and speech as presented, patients have difficulty swallowing, bleeding, volume increases and sometimes infection may be a complication present in these patients.<sup>1,6-8</sup>

It is indispensable a careful analysis for the diagnosis of bone lesions, with a complete radiographic examination such as occlusal and panoramic radiographs is required. Computed tomography can be used for delineation of the region and request angiography or arteriography to visualize the vascular component of the lesion. Clinical examination is essential for better clinical conduct. Aspiration biopsies in this type of pathology are important to avoid unnecessary surgery or bleeding emergencies.<sup>8,9</sup> With definitive diagnosis, treatment must be discussed and evaluated, because often the patient follow-up is required and no intervention for repair or removal of the lesion is necessary. This conduct is justified because sometimes the pathology has difficult resolution and high surgical risk.<sup>6,7,9</sup> Several treatment modalities are available and selection dependent on the size of the lesion, patient's age, comorbidities and symptomatology evolution. Sclerosing agents such as sodium morrhuate and absolute ethanol may be injected into the lesion, inducing an inflammatory response resulting in fibrosis and obliteration of the vessels.<sup>9,10</sup> Furthermore, hot water and hypertonic glucose solution are also used in sclerotherapy of vascular malformations.<sup>11</sup>

The clinical treatment can be performed with drugs of local use (topical or intralesional) or systemic use (oral or injectable). The drugs most commonly used are corticosteroids and alpha-Interferon. A recent indication of the use of beta blockers is still under investigation, but appears promising.<sup>2,11</sup> Ionizing radiation can also be used, promoting the obliteration of the vascular component of the lesion and exclude surgery intervention.<sup>4</sup> Nevertheless, the adverse effects of radiotherapy leads to discussion about this type of treatment, especially in mandibular region as in the case of two patients reported. In this type of treatment, protocols already discussed in the literature for oral care to patients should be performed, such as use of mouthwash,

adequacy of oral cavity and necessary teeth extractions prior to radiotherapy.<sup>12</sup> Embolization of large vessels feeding the lesion is often recommended. It decreases main blood vessels diameter that nourish the lesion<sup>7,9,10</sup>, leading to a less bleeding surgery, with easier resolution.

Surgical intervention is generally accepted as a definitive treatment with en bloc resection or curettage recommended.<sup>10</sup> Immediate reconstruction of the area is indicated when possible. Extension beyond the lesion reduces the risk of disruption and may reduce the risk of catastrophic hemorrhage. Ligation of feeder vessels should precede the removal of the lesion. Also, momentarily stopping of the blood vessels that nourish the lesion is an option during surgery. Even with all pre-operative care, surgery with abundant bleeding can occur and blood transfusion may be needed.<sup>6,9,13,14</sup>

### Conclusion

It may be noted that the final diagnosis of this vascular lesion is difficult and if not done satisfactorily can lead to huge problems with hard resolutions. Patient care by a multidisciplinary team using an emergent treatment approach is important for sustained treatment results. The treatment should be reasonably programmed and analyzed - patient's age, sequel, technical difficulty of surgery, symptoms, location of disease, presence or not of multidisciplinary time and also the surgeon's skill in handling this type of injury - these factors must be taken into account for choice of treatment this kind of lesion. Although intra-osseous vascular alterations are rare, there is a need to be listed as a differential diagnosis from other lesions of similar characteristics, with this would be possible to avoid surgical risks to the patient and a plan of treatment of the lesion can be done in a better way.

### Acknowledgement

We would like to acknowledge all the staff members of department of Oral Pathology for their support and guidance.

### Author Affiliations

1.Dr.Cleveson Patussi, Resident, 2.Dr.Laurindo Moacir Sassi, Chief, 3.Dr.Regiane Benez Bixofis, Resident, 4.Dr.Fernando Luiz Zanferrari, Clinical staff, 5.Dr.Roberta Targa Stramandinoli-Zanicotti, Clinical staff, 6.Dr.Juliana Lucena Schussel, Clinical staff, Department of Oral and Maxillofacial Surgery, Erasto Gaertner Hospital, Brazil.

## References

1. Tucci FM, De Vincentiis GC, Sitzia E, Giuzio L, Trozzi M, Bottero S. Head and neck vascular anomalies in children. *Int J Pediatr Otorhinolaryngol.* 2009;73:S71-6.
2. Hiraki PY, Goldenber DC. Diagnosis and treatment of infantile hemangioma. *Rev Br Cir Plást.* 2010;25(2):388-97.
3. Singh V, Bhardwaj PK. Arteriovenous malformation of mandible: Extracorporeal curettage with immediate replantation technique. *Nat J Maxillofac Surg.* 2010;1(1):45-9.
4. Cheng NC, Lai DM, Hsieh MH, Liao SL, Chen YB. Intraosseous Hemangiomas of the facial bone. *Plast Reconstr Surg.* 2006;117(7):2366-72.
5. Ozdemir R, Alagoz S, Uysal AC, Unlu RE, Ortak T, Sensoz O. Intraosseous Hemangioma of the Mandible: A Case Report and Review of the Literature. *J Craniofac Surg.* 2002;13(1):38-43.
6. Fornatora M, Yen AH, Yang J, Pliskin M, Quinn PD. Quinn Clinico-Pathologic Conference: Case 1. *Head Neck Pathol.* 2009;3(4):283-5.
7. Koshy CG, Keshava SN, Moses V, Sen S. Case report: Combined transarterial and direct approaches for embolization of a large mandibular arteriovenous malformation. *Indian J Radiol Imaging.* 2011;21(1):6–9.
8. Ella B, Lanotte A, Sedarat C, Fricain JC. Arteriovenous malformation of the maxilla complicated by a local pathogen infection. *BMJ Case Rep.* 2013;31;2013. doi: 10.1136/bcr-2012-007617
9. Churojana A, Khumtong R, Songsaeng D, Chongkolwatana C, Suthipongchai S. Life-threatening arteriovenous malformation of the maxilla-mandibular region and treatment outcomes. *Interv Neuroradiol.* 2012;18(1):49-59.
10. Colin A. Eliot, James T. Castle. Intraosseous Hemangioma of the Anterior Mandible. *Head Neck Pathol.* 2010;4(2):123-5.
11. Paramasivam S, Niimi Y, Fifi J, Berenstein A. Onyx embolization using dual-lumen balloon catheter: Initial experience and technical note. *J Neuroradiol.* 2013;40(4):294-302.
12. Sassi LM, Machado RA. Head and neck pre-radiotherapy protocol. *Revis Bras. Cir. Cabeça Pescoço.* 2009;38(3):208-10.
13. Gómez-Oliveira G, García-Rozado A, Luaces-Rey R. Intraosseous mandibular hemangioma. A case report and review of the literature. *Med Oral Pathol Oral Cir Bucal.* 2008;13(8):E496-8.
14. Hansen T, Kunkel M, Katenkamp D, Eletr S, Wagner W. Hemangioma of the mandible: case report with special emphasis on bone degradation. *Oral Maxillofac Surg.* 2009;13(4):239-42.

### Corresponding Author

Dr. Cleverson Patussi,  
 Rua Dr. Ovandedo Amaral, 201  
 81520-060 Curitiba, Brazil.  
 Email: cleversonpatussi@hotmail.com  
 Ph: 55 41 3361-5000

Source of Support: Nil, Conflict of Interest: None Declared.