



Effect of Radiotherapy on Osseointegration of Dental Implants Immediately Placed in Postextraction Sites of Minipigs Mandibles

Roberta Targa Stramandinoli-Zanicotti, DDS, PhD,* Laurindo Moacir Sassi, DDS, PhD,†
Juliana Lucena Schussel, DDS, PhD,‡ Maria Fernanda Torres, MV, PhD,§ Sergio Araquem Matos Ferreira, MD,||
and André Lopes Carvalho, MD, PhD¶

Head and neck cancer (HNC) is one of most frequent tumors in Brazil. At early stage, the treatment of choice is usually radiotherapy (RT) or surgery alone, whereas advanced HNC is often resected by surgery, followed by postoperative external beam RT or brachytherapy.^{1,2}

Over the past years, the use of dental implants (DI) in oral cancer patients treated with surgery and RT has increased and has become an important treatment modality in oral rehabilitation because surgical treatment of HNC frequently results in defects that challenge conventional prosthetic rehabilitation.³⁻⁵ Patients with HNC often need oral rehabilitation as part of functional and

Introduction: The aim of this study was to compare the osseointegration and the survival of dental implants (DIs) immediately placed in postextraction sites, in mandibles of minipigs that underwent radiotherapy (RT).

Materials and Methods: Twelve Brazilian minipigs were divided into the following groups: A, control; B, implants placement 15 days before RT; C, implants placement 3 months after RT. Implant loss rate (ILR), fibrointegration rate (FIR), bone-implant contact (BIC), and bone density inside the threads (BDIT) were determined in each group 90 days after implantation.

Results: ILR was higher in group C (68.7%) than in groups B (28.1%) and A (21.9%), ($P = 0.001$). FIR was more frequent in group C

(30%) than in groups B (21.7%) and A (4%), although not statistically significant. The averages of BIC and BDIT were, respectively, 33.1 and 41.5 in group C; 18.5 and 26.6 in group B; and 11.5 and 16.3 in group A ($P = 0.003$ for both variables).

Conclusions: RT showed a negative effect in periimplant bone regeneration. The implants placement before RT showed better results compared with the implants performed after RT, suggesting that DIs in head and neck cancer patients must be placed before RT or simultaneously during ablative tumor surgery. (Implant Dent 2014;23:560-564)

Key Words: dental implants, oral cancer, radiotherapy, immediate implant placement, animal model, minipigs

*Postgraduate Programme in Oncology, University of São Paulo, São Paulo, SP, Brazil; Staff of Oral and Maxillofacial Surgery Department, Erasto Gaertner Hospital, Curitiba, PR, Brazil.
†Chief of Oral and Maxillofacial Surgery Department, Erasto Gaertner Hospital, Curitiba, PR, Brazil.
‡Staff of Oral and Maxillofacial Surgery Department, Erasto Gaertner Hospital, Curitiba, PR, Brazil.
§Veterinary of Experimental Surgery Laboratory and Biotarium, Positivo University, Curitiba, PR, Brazil; Associate Professor of Federal University of Paraná, Curitiba, PR, Brazil.
||Chief of Radiotherapy Department, Erasto Gaertner Hospital, Curitiba, PR, Brazil.
¶Scientific Director of Head and Neck Surgery and Otorhinolaryngology Department, Hospital de Câncer de Barretos, Barretos, SP, Brazil; Research Advisor of Postgraduate Programme in Oncology, University of São Paulo, São Paulo, SP, Brazil.

Reprint requests and correspondence to: Roberta Targa Stramandinoli-Zanicotti, DDS, MSc, Hospital Erasto Gaertner, Rua Dr. Ovande do Amaral, 201, Curitiba, PR 81.520-060, Brazil, Phone/Fax: +55 (41) 33229329, E-mail: robertatsz@usp.br

aesthetic recovery. However, the use of DI in these patients is still controversial.

Patients who underwent RT are susceptible to secondary effects and orofacial complications. After RT, the vascularization and regenerative ability of irradiated tissues can be decreased and the process of osseointegration may be impaired.^{6,7} Osteoradionecrosis (ORN) is one of the most severe and devastating late oral complications of RT in patients with HNC,^{2,8}

and it can be induced by surgical procedures such as tooth extractions and placement of DIs. Marx and Johnson⁹ believed that the main process for ORN was the formation of hypocellular tissue that occurs after radiation, leading to hypoxia and hypovascularity and then to tissue breakdown.

The aim of this study was to compare the osseointegration and the survival of DIs immediately placed in

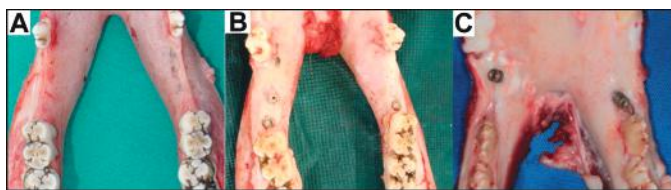

Fig. 1. Clinical features of the mandibles 90 days after implantation. **A**, Group A (absence of implant exposure); **B** group B (presence of screw cover exposed) and **C** group C (presence of implant screw exposure and implant mobility).

postextraction sites, in mandibles of minipigs 15 days before RT, 3 months after RT and in a nonirradiated bone.

MATERIALS AND METHODS

Twelve male Brazilian minipigs (Minipig Br1; Minipig Pesquisa & Desenvolvimento LTDA, Sao Paulo, Brazil), 18 months old, weighting 30–40 kg were used in this study. All minipigs were housed together with free access to food and water.

The animals were divided into 3 different groups: group A (nonirradiated group); group B (implants placement 15 days before RT), and group C (implants placement 3 months after RT).

The Ethics and Research Committee at the Positivo University, Curitiba, Paraná, Brazil, approved this study protocol (001/2009). All guidelines regarding the care of animal research subjects were strictly followed.

Radiotherapy

The total radiation dosage for each side of the mandible was 24 Gy (Cobalt 60, Theratron 780C; MDS Nordion, Ontario, Canada), divided into 3 doses of 8 Gy with a 7-day interval for each dose.^{10,11} Using the ratio α/β of 2.5 equivalence, this dose was biologically equivalent to approximately 56 Gy in the human mandible (28 exposures of

2 Gy each), the protocol to RT to HNC treatment.

For the RT, animals received an intramuscular injection of a combination of ketamine hydrochloride 10% (10 mg/kg) and xylazine hydrochloride 2% (5 mg/kg), followed by intravenous administration of sodium pentobarbital 5% (5 mg/kg).

Surgical Procedure

For the surgical procedure, after the same premedication described for RT, animals underwent oroantral intubation and anesthesia was induced by isoflurane (Cristália, São Paulo, Brazil), maintained in oxygen using standard equipment and monitoring. The same operator performed all surgeries.

The mouth was flushed with a 0.1% chlorhexidine solution. Extraction of the third and fourth premolar in each hemimandible was achieved after longitudinal sectioning and using root elevators and extraction forceps. Based on intraoral radiographs and intraoperative clinical evaluation, 4 titanium

implants of appropriate length and width (ConeMorse; Neodent, Curitiba, Brazil) were placed in the fresh extraction sockets of each hemimandible. A resorbable bovine membrane was applied to protect the bone and implants, and the gingival flaps were sutured using an interrupted suture pattern with Vicryl Rapid 2/0 (Ethicon, São José dos Campos, Brazil). A total of 32 implants were placed in each group.

As postoperative care, animals received morphine (3 mg/kg) and kinetomax (Bayer, São Paulo, Brazil). The animals were fed only with food powder. No specific oral hygiene procedures were used after surgery.

The minipigs were killed at 90 days after implantation. The mandibular segments of interest were isolated using a jigsaw. Macroscopic analysis was performed for the presence of exposed implants, implant mobility, and signs of infection. X-ray of the bone blocks were taken and implant loss rate (ILR) in each group was determined.

Histological Processing

The bone blocks were placed in 10% buffered formalin for 2 weeks and then they were embedded in acrylic resin, according to the Donath and Breuner¹² protocol. Each block was sectioned parallel with the long axis of the implant, using a cutting machine (EXAKT-Cutting Grinding System 400CP; Kulzer, Norderstedt, Germany). Each section

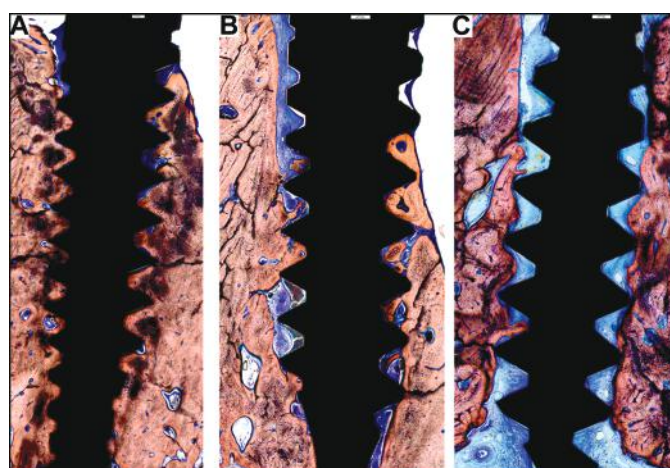


Fig. 2. Histological features of samples of each group studied 90 days after implantation. The bone-implant interface showed a mineralized bone matrix in intimate contact with the implant surface more pronounced for the group A and B than group C, where a large amount of nonmineralized tissue (blue) was presented. Steven's blue and Alizarin red S (bars = 100 μ m).

Table 1. ILR 90 Days After Implantation in Minipigs Mandible

Group	ILR (%)	Median (Min–Max)	<i>P</i> *
A	21.9	1.0 (0–2.0)	0.001
B	28.1	1.0 (0–2.0)	
C	68.7	2.5 (2.0–4.0)	

*Nonparametric Kruskal-Wallis test; *P* < 0.05 represents a significantly statistical difference.

Group A indicates control group, no RT; Group B, implants placement 15 days before RT; Group C, implants placement 3 months post-RT; ILR, implant loss rate.

Table 2. FIR Assessment 90 Days After Implantation in Minipigs Mandible

Group	FIR (%)	Median (Min–Max)	P*
A	4.0	0 (0–33.3)	0.114
B	21.7	29 (0–50.0)	
C	30.0	25 (0–100)	

*Nonparametric Kruskal-Wallis test; P < 0.05 represents a significantly statistical difference. FIR indicates fibrointegration rate; Group A, control group, no RT; Group B, implants placement 15 days before RT; Group C, implants placement 3 months post-RT.

was polished (Politriz Petalográfica DP-10, Panambra/Struers, Cambuci, Brazil), mounted on acrylic slides and the resulting 40-µm thick mounted sections were further ground and polished to a thickness of 20 µm. For histological and histomorphometric analyses, sections were stained with Stevenel’s blue and alizarin red S,¹³ which stain in red the mineralized tissue and in blue the fibrous tissue.

Histological Analyses

Histological assessment was divided in 3 criteria: (1) fibrointegration rate (FIR); (2) bone-implant contact (BIC); and (3) bone density inside the threads (BDIT).

Fibrointegration (FI) corresponded to samples that showed no mineralized bone matrix in contact with the surface of the implant or around the threads on both sides. Samples that showed any amount of mineralized bone tissue in contact with the implant surface were submitted to histomorphometric

Table 3. BIC and BDIT Assessment 90 Days After Implantation in Minipigs Mandible

Analysis	Group	Average (Min–Max)	SD	P*
BIC	A	33.1 (0–67.2)	18.0	0.003
	B	18.5 (0–69.3)	17.9	
	C	11.5 (0–28.4)	12.1	
BDIT	A	41.5 (0–78.8)	21.0	0.003
	B	26.6 (0–75.5)	21.4	
	C	16.3 (0–46.8)	17.6	

*Nonparametric Kruskal-Wallis test; P < 0.05 represents a significantly statistical difference. BIC indicates bone implant contact; BDIT, bone density inside the threads; Group A, control group, no RT; Group B, implants placement 15 days before RT; Group C, implants placement 3 months post-RT; SD, standard deviation.

analysis for the percentage of BIC and BDIT. The 2 sides of each implant were analyzed separately and then the average of the measurements was calculated. To establish the percentage of BIC, the total of mineralized bone in contact with the surfaces of the implants were determined, multiplied by 100 and divided by the total linear measurement of the implant. For BDIT analysis, the area of the newly formed bone inside all threads was determined, multiplied by 100 and divided by the total area inside the threads.

Statistical Analysis

Continuous variables were presented as average, median maximum, minimum, and standard deviations, and categorical variables were presented as frequencies and percentages. To compare the 3 groups, the nonparametric Kruskal-Wallis exact test was applied. To compare the groups in pairs, the Mann-Whitney test was applied. Values of P < 0.05 were

considered statistically significant. Analysis was performed with the SPSS V.14 software package.

RESULTS

Clinical and Radiographic Evaluation

All pigs were killed 90 days after implantation. A clinical examination was performed to assess the presence of the implant in the mouth. All animals showed total healed mucosa in the operated region. No sign of active infection was evidenced. In group A, all implants were covered by gingival mucosa. In group B, 6 implants had the screw cover exposed and in group C, 4 implants had some threads exposed, 2 of which were mobile (Fig. 1).

Radiographic images confirmed the presence of the implants. The ILR was higher in group C (68.7%) than in groups B (28.1%) and A (21.9%), with a significant statistical difference (Table 1). The groups were compared in pairs and showed significance between groups A and C (P < 0.001) and groups B and C (P < 0.001), but no statistical difference among groups A and B (P = 0.530).

Histological Evaluation

The bone-implant interface showed a mineralized bone matrix in intimate contact with the implant surface more pronounced for the group A and B than group C (Fig. 2). The FIR was more frequent in the group C, without statistical significance (Table 2). Particularly, in group C, a soft tissue formation around the implant was observed (Fig. 3). Regarding bone formation around the implants, the results showed a statistically significant difference when comparing the 3 groups (Table 3). When we compared the groups in pairs for

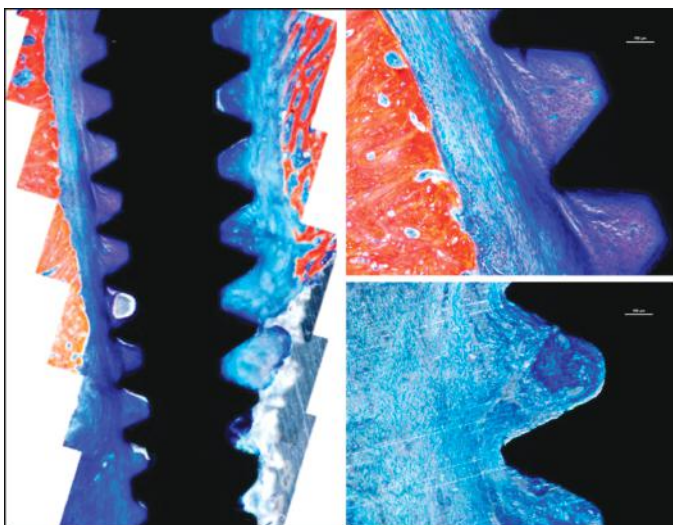


Fig. 3. A case of fibrointegration on group C: no bone formation in contact with the implant. Stevenel’s blue and Alizarin red S (bars = 100 µm).

BIC and BDIT, the Mann-Whitney test found significant statistical difference among groups A and B ($P = 0.005$ and $P = 0.009$, respectively) and groups A and C ($P = 0.002$ and $P = 0.001$, respectively), but no significant difference among groups B and C ($P = 0.337$ and $P = 0.210$, respectively).

DISCUSSION

The goal of HNC treatment is to cure and maintain function. It depends on tumor site, size, histologic features stage as well as impact on patient's quality of life¹⁴. Head and neck RT affects all oral structures such as maxillary bones, salivary glands, oral mucosa, vasculature, and muscle with several long-term side effects. For these reason, patients with oral cancer require multidisciplinary management involving surgeons, radiotherapists and medical oncologists, dentists, and allied health specialists. DI is an important component of multidisciplinary rehabilitation after surgical resection. In most of the cases, it is the only way to oral rehabilitation. However, negative effects of radiation, including ORN, are well documented in the literature, and early loss of implants in irradiated bone has been reported.¹⁵

A meta-analysis of the literature of the years 1990–2006 showed a significant difference in implant survival between nonirradiated and irradiated patients with a higher implant survival in the nonirradiated bone¹⁶. A recent study reported a failure rate of 24% for implants placed in HNC patients at a 5-year follow-up.¹⁷

The effects of radiation on the bone tissue are an essential factor affecting the DI survival. Initial changes in bone caused by RT arise from direct injury to the remodeling system.¹⁵ Different studies on irradiated animals^{18,19} and humans treated with RT^{20–22} have identified the radiation dosage that is able to ensure a long-term implant survival at 50 Gy. Radiation dosages exceeding 40–50 Gy may impair bone healing and implant osseointegration.²³ In this study, the total dose that the animals received was biologically equivalent to approximately 56 Gy in the human mandible. The animals that received this radiation dosage before the

implant placement had the highest ILR and the lowest bone formation around the implants. Previous publications using animal models have shown that implant stability during osseointegration may be impaired in irradiated jaws because of the decrease in bone vascularity and vitality¹¹; however, in the short term, the bone mineral density seems to be similar to that of nonirradiated alveolar bone.¹⁰

BR-1 minipigs share similar anatomy, physiology, and physiopathology with humans and have been described as a satisfactory animal model for different purposes.²⁴ Although biological parameters are similar to humans, hygiene and parafunctional habits in minipigs can be harmful for adequate implant healing and osseointegration. Implementation of a soft diet in the first weeks of gingival healing might substantially decrease masticatory forces on the implant sites in our study. A prerequisite for immediate postextraction implant placement is the atraumatic extraction of the tooth to preserve the integrity of the thin lingual and buccal cortical plates.²⁵ It is generally accepted that the chances for successful osseointegration of an implant in the oral environment increase when a stress-free nonfunctional healing period can be provided²⁶ and when implants are used of a wider and/or longer length than the initial extraction socket.²⁷

Another responsible factor for a successful osseointegration seems to be the interval between the end of RT and the DI placement. Various studies^{3,5,28} have investigated the required time interval between RT and implant installation that may influence osseointegration; however, the results remain debatable.

Some authors²⁹ accept a 6-month interval, whereas others¹⁸ recommend a period between 13 and 24 months from RT. Failure rate decreases with a lapse of 24 months or more.⁴ In a recent study, less time seems not able to ensure the bone quality and vascularization, compromising the osseointegration. Implant losses in irradiated patients occurred mainly because of periimplant infection or asymptomatic periimplant bone loss and consecutive integration.³⁰ We performed the implant placement 3 months after RT, and the effects of irradiation regarding implant lost and bone

formation were statically significant compared with the control group.

In our study, the ILR in irradiated animals (group C) was 3 times higher than in the animals that did not receive RT (group A), agreeing with studies that also related that irradiation has negative effects on the survival of DI.^{10,11,28} The RT performed 15 days after implant placement showed no statistical difference with the nonirradiated group. These data support other studies in which prosthodontics rehabilitation of oral function in HNC patients with DIs must be placed before RT or simultaneously during ablative tumor surgery.³

The FI is a fibrous tissue encapsulation and the bacterial colonization around the implant, and it is a failure in the osseointegration. Although no statistical significance could be calculated, the FIR found in our study was more frequent in group C (30%) compared with groups B (21.7%) and A (4%). Marx and Johnson⁹ believed that the formation of hypocellular tissue that occurs after radiation, leading to hypoxia and hypovascularity, is the main cause of failures in DI osseointegration. These events are associated with a periimplant infection or asymptomatic periimplant bone loss leading to a fibrous tissue formation around the implant and consecutive integration loss.^{30,31}

The tissue contact with the DI is the result of a process of new bone growth that involves continuous modeling and remodeling. Thus, it is important to understand that bone-implant integration is a dynamic process. The formation and stability of new bone around the implant is a combination of resorption and bone apposition. When we analyzed the samples by light microscopy, we found lower bone formation in irradiated groups than control group, with statistically significant between the groups. Both variables (BIC and BDIT) were reduced in groups C (11.5 and 16.3, respectively) and B (18.5 and 26.6, respectively) compared with group A (33.1 and 41.5, respectively).

CONCLUSIONS

The results showed a negative effect of RT in periimplant bone regeneration. The implant loss was 3 times

higher in irradiated bone than in non-irradiated bone. Osseointegration was impaired in irradiated bone. The implants placement 15 days before RT showed better results compared with the implants performed 3 months after RT, suggesting that prosthodontics rehabilitation with DIs in patients who need RT must be placed before RT or simultaneously during ablative tumor surgery.

DISCLOSURE

The authors claim to have no financial interest, either directly or indirectly, in the products or information listed in the article.

ACKNOWLEDGMENTS

The authors express our sincere thanks to the staff members of the Erasto Gaertner Hospital and Department of Experimental Surgery of Positivo University, especially Melissa Funchal, Vanderlei Muller and Cirlei Aparecida Ribeiro do Silva, and to Sheila Albuquerque Freire and Eva Aparecida Rocha for the care of the pigs. We also thank Neodent (Curitiba, Paraná, Brazil) for donating the implants used in this research. The corresponding author received a PhD scholarship from CAPES Foundation (Ministry of Education of Brazil, Brasília-DF, Brazil). Part of this research received financial support from Araucaria Foundation (Curitiba, Paraná, Brazil).

REFERENCES

- Forastiere A, Koch W, Trotti A, et al. Head and neck cancer. *N Engl J Med*. 2001;345:1890–1900.
- Marx RE. Osteoradionecrosis: A new concept of its pathophysiology. *J Oral Maxillofac Surg*. 1983;41:283–288.
- Schoen PJ, Raghoebar GM, Bouma J, et al. Prosthodontic rehabilitation of oral function in head-neck cancer patients with dental implants placed simultaneously during ablative tumour surgery: An assessment of treatment outcomes and quality of life. *Int J Oral Maxillofac Surg*. 2008;37:8–16.
- Cuesta-Gil M, Ochandiano Caicoya S, Riba-Garcia F, et al. Oral rehabilitation with osseointegrated implants in oncologic patients. *J Oral Maxillofac Surg*. 2009;67:2485–2496.
- Schepers RH, Slagter AP, Kaanders JH, et al. Effect of postoperative radiotherapy on the functional result of implants placed during ablative surgery for oral cancer. *Int J Oral Maxillofac Surg*. 2006;35:803–808.
- Ihde S, Kopp S, Gundlach K, et al. Effects of radiation therapy on craniofacial and dental implants: A review of the literature. *Oral Surg Oral Med Oral Pathol Oral Radiol Endod*. 2009;107:56–65.
- Granstrom G, Tjellstrom A, Branemark PI. Osseointegrated implants in irradiated bone: A case-controlled study using adjunctive hyperbaric oxygen therapy. *J Oral Maxillofac Surg*. 1999;57:493–499.
- Curi MM, Dib LL, Kowalski LP. Management of refractory osteoradionecrosis of the jaws with surgery and adjunctive hyperbaric oxygen therapy. *Int J Oral Maxillofac Surg*. 2000;29:430–434.
- Marx RE, Johnson RP. Studies in the radiobiology of osteoradionecrosis and their clinical significance. *Oral Surg Oral Med Oral Pathol*. 1987;64:379–390.
- Verdonck HW, Meijer GJ, Laurin T, et al. Implant stability during osseointegration in irradiated and non-irradiated minipig alveolar bone: An experimental study. *Clin Oral Implants Res*. 2008;19:201–206.
- Verdonck HW, Meijer GJ, Nieman FH, et al. Quantitative computed tomography bone mineral density measurements in irradiated and non-irradiated minipig alveolar bone: An experimental study. *Clin Oral Implants Res*. 2008;19:465–468.
- Donath K, Breuner G. A method for the study of undecalcified bones and teeth with attached soft tissues. The Sage-Schliff (sawing and grinding) technique. *J Oral Pathol*. 1982;11:318–326.
- Maniatopoulos C, Rodriguez A, Deporter DA, et al. An improved method for preparing histological sections of metallic implants. *Int J Oral Maxillofac Implants*. 1986;1:31–37.
- Chambers MS, Garden AS, Kies MS, et al. Radiation-induced xerostomia in patients with head and neck cancer: Pathogenesis, impact on quality of life, and management. *Head Neck*. 2004;26:796–807.
- Tanaka TI, Chan HL, Tindle DI, et al. Updated clinical considerations for dental implant therapy in irradiated head and neck cancer patients. *J Prosthodont*. 2013;22:432–438.
- Schiegnitz E, Al-Nawas B, Kämmerer PW, et al. Oral rehabilitation with dental implants in irradiated patients: A meta-analysis on implant survival. *Clin Oral Investig*. 2014;18:687–698.
- Dholam KP, Pusalkar HA, Yadav PS, et al. Implant-retained dental rehabilitation in head and neck cancer patients: An assessment of success and failure. *Implant Dent*. 2013;22:604–609.
- Ohrnell LO, Branemark R, Nyman J, et al. Effects of irradiation on the biomechanics of osseointegration. An experimental in vivo study in rats. *Scand J Plast Reconstr Surg Hand Surg*. 1997;31:281–293.
- Taylor TD, Worthington P. Osseointegrated implant rehabilitation of the previously irradiated mandible: Results of a limited trial at 3 to 7 years. *J Prosthet Dent*. 1993;69:60–69.
- Esser E, Neukirchen S, Wagner W. Comparative studies of Branemark implants in the irradiated and not irradiated mandible [in German]. *Mund Kiefer Gesichtschir*. 1999;3(suppl 1):S125–S129.
- Ali A, Patton DW, el-Sharkawi AM, et al. Implant rehabilitation of irradiated jaws: a preliminary report. *Int J Oral Maxillofac Implants*. 1997;12:523–526.
- Andersson G, Andreasson L, Bjelkengren G. Oral implant rehabilitation in irradiated patients without adjunctive hyperbaric oxygen. *Int J Oral Maxillofac Implants*. 1998;13:647–654.
- Beumer J 3rd, Roumanas E, Nishimura R. Advances in osseointegrated implants for dental and facial rehabilitation following major head and neck surgery. *Semin Surg Oncol*. 1995;11:200–207.
- Oltamari PV, Navarro RL, Henriques JF, et al. Dental and skeletal characterization of the BR-1 minipig. *Vet J*. 2007;173:399–407.
- Vlaminck L, Gorski T, Huys L, et al. Immediate postextraction implant placement in sheep's mandibles: A pilot study. *Implant Dent*. 2008;17:439–450.
- Hahn J, Babbush C. Immediate implant placement after extraction: Contemporary materials and techniques. In: Babbush C, ed. *Dental Implants—The Art and Science*. Philadelphia, PA: W.B. Saunders; 2001:305–334.
- Missika P, Abbou M, Rahal B. Osseous regeneration in immediate postextraction implant placement: A literature review and clinical evaluation. *Pract Periodontics Aesthet Dent*. 1997;9:165–175; quiz 76.
- Cao Y, Weischer T. Comparison of maxillary implant-supported prosthesis in irradiated and non-irradiated patients. *J Huazhong Univ Sci Technol Med Sci*. 2003;23:209–212.
- Hancock PJ, Epstein JB, Sadler GR. Oral and dental management related to radiation therapy for head and neck cancer. *J Can Dent Assoc*. 2003;69:585–590.
- Sammartino G, Marenzi G, Cioffi I, et al. Implant therapy in irradiated patients. *J Craniofac Surg*. 2011;22:443–445.
- Guillem-Marti J, Delgado L, Godoy-Gallardo M, et al. Fibroblast adhesion and activation onto micro-machined titanium surfaces. *Clin Oral Implants Res*. 2013;24:770–780.